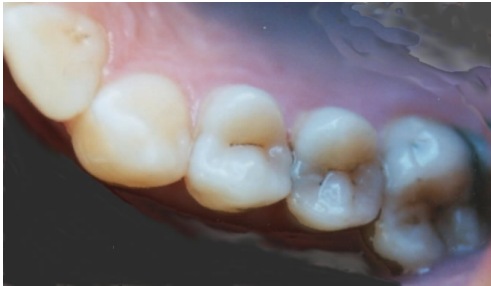
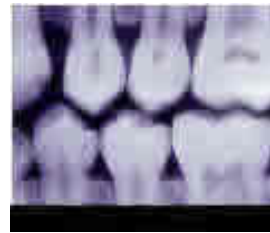

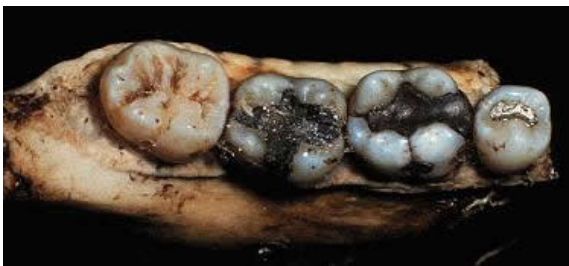These are teeth were recovered from burned victims. Compare pre- and post-mortem dental records and work with the DNA expert to determine to identity of the bodies found at the crime scene.



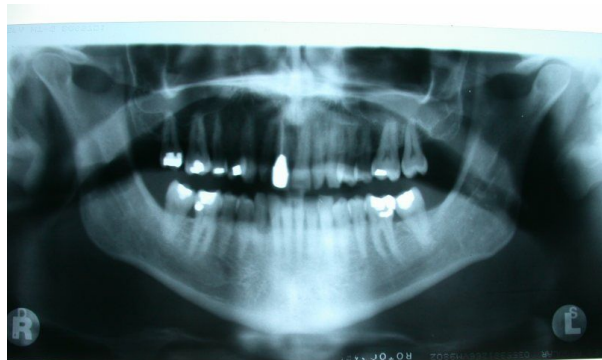Teeth photographed from unidentified female; left side, lower mandible including incisor, canine, two premolars and one molar.



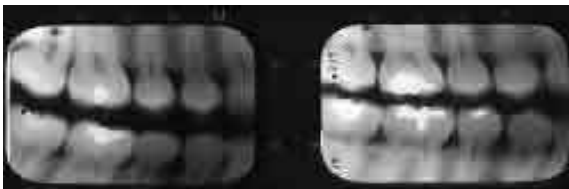
Bite wing obtained from Elaine Staw's dental records showing left side of mouth, dated August 20th 1999.



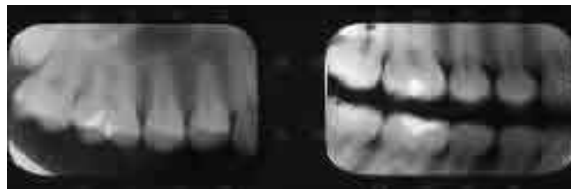Teeth photographed from unidentified male; right side, lower mandible including one premolar and three molars.



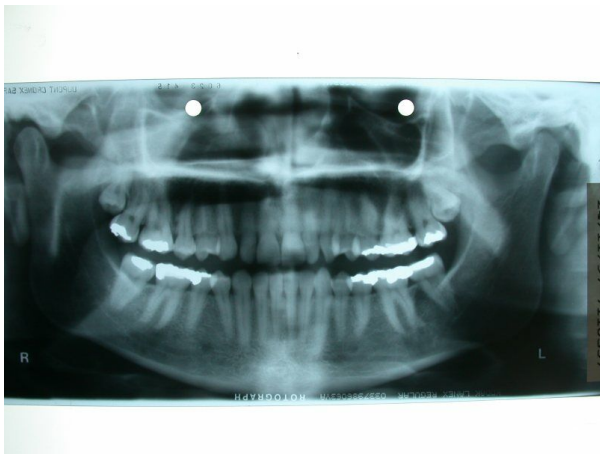Panoramic x-ray of Jack Straw showing all teeth, dated January 8th, 2002.



Bite wings obtained from Talbot Straw's dental records showing left and right side of mouth respectively, dated February 24th, 2000.



Bite wings obtained from dental records of Mike Boyce, showing top left side and right side of mouth respectively, dated March 15th, 2001.



Panoramic x-ray of Richard Boyce showing all teeth, dated April 22nd, 2001.